

CASE REPORT

## Subacute Combined Degeneration of the spinal cord: case report

### Degeneración combinada subaguda de la médula espinal: presentación de caso

Lisbel Garzón Cutiño<sup>1</sup>  , Deborah Cabrera Rodríguez<sup>2</sup> , Maytee Olivera Vega<sup>1</sup> , Amanda López Reyes<sup>2</sup> ,  
Luis Daniel Guzmán Camps<sup>2</sup> , Lianet Pérez Esquivel<sup>1</sup> 

<sup>1</sup>Hospital Docente Clínico Quirúrgico “Dr. Miguel Enríquez”, Servicio de Neurología. La Habana, Cuba.

<sup>2</sup>Universidad de Ciencias Médicas, Facultad de Ciencias Médicas “Miguel Enríquez”. La Habana, Cuba.

Cite as: Garzón Cutiño L, Cabrera Rodríguez D, Olivera Vega M, López Reyes A, Guzmán Camps LD, Pérez Esquivel L. Subacute Combined Degeneration of the spinal cord: case report. Interdisciplinary Rehabilitation / Rehabilitación Interdisciplinaria. 2025; 5:27. <https://doi.org/10.56294/ri202527>

Submitted: 05-03-2024

Revised: 08-08-2024

Accepted: 15-01-2025

Published: 16-01-2025

Editor: PhD. Nicola Luigi Bragazzi 

Correspondence author: Lisbel Garzón Cutiño 

#### ABSTRACT

**Introduction:** subacute Combined Degeneration is a neurological condition that manifests itself by a degeneration of the nerve pathways in the spinal cord affecting the posterior and lateral cords. It is caused by a deficiency of vitamin B12 which affects the brain and peripheral nerves. Magnetic Resonance Imaging (MRI) may not reveal significant changes initially. Electrophysiological studies like somatosensory evoked potentials (SSEPs) are useful for early detection.

**Case report:** a 58-year-old male patient who denies any personal pathological history. He comes to the clinic due to periods of cramps in the lower limbs and ataxia. After two months, he begins to experience loss of muscle strength in both lower limbs.

**Conclusions:** prompt identification and intervention are vital for the recovery from the deficiency.

**Keywords:** Subacute Combined Degeneration; Posterior Cords; Vitamin B12 Deficiency.

#### RESUMEN

**Introducción:** la Degeneración Combinada Subaguda es una condición neurológica que se manifiesta por una degeneración de las vías nerviosas en la médula espinal afectando los cordones posteriores y laterales. Es causada por un déficit de vitamina B12 lo cual afecta al cerebro y a los nervios periféricos. Inicialmente los estudios de Imagen por Resonancia Magnética no revelan cambios significativos jugando los estudios neurofisiológicos un rol esencial.

**Reporte de caso:** paciente masculino de 58 años de edad que niega Antecedentes Patológicos Personales. Acude a consulta por presentar periodos de calambres en miembros inferiores y ataxia. A los 2 meses comienza con pérdida de la fuerza muscular en ambos miembros inferiores.

**Conclusiones:** la detección y tratamiento precoz es crucial en la recuperación del déficit.

**Palabras clave:** Degeneración Combinada Subaguda; Cordones Posteriores; Déficit De Vitamina B12.

#### INTRODUCTION

Subacute Combined Degeneration (SCD) is a neurological disorder characterized by progressive degeneration of nerve pathways in the spinal cord.<sup>(1,2)</sup> The term SCD emphasizes the clinical and pathological involvement of the posterior (dorsal) and lateral columns of the spinal cord.<sup>(3)</sup> It generally results from vitamin B12 deficiency,

adversely affecting the central and peripheral nervous systems.<sup>(2)</sup> Around 50 % of individuals with vitamin B12 deficiency and neurological symptoms present with myelopathy, either alone or alongside peripheral neuropathy.<sup>(3)</sup>

Vitamin B12 is fundamental to nervous system health and myelin formation. In SCD, initially, the myelin sheath swells, followed by myelin breakdown and macrophage infiltration. Over time, axonal degeneration progresses, accompanied by gliosis.<sup>(4)</sup>

The primary causes of vitamin B12 deficiency include insufficient dietary intake, decreased intrinsic factor necessary for absorption, gastrointestinal disorders, bacterial overgrowth and prior gastric surgery.<sup>(5)</sup>

The initial clinical manifestations include paresthesia, which may progress to sensory ataxia, progressive weakness, instability, and pyramidal tract involvement.<sup>(1)</sup>

**CASE PRESENTATION**

A 58-year-old male patient with no significant medical history presented with intermittent cramps in the lower limbs. He administered 3 doses (unknown mcg) of vitamin B12 intramuscularly without a medical prescription and he reported a mild improvement of the symptoms. After two months, he developed sensory ataxia and progressive muscle weakness in both lower limbs.

*Physical Examination (Positive Findings)*

Neurological Examination: Spastic paraparesis, sensory level at T8 (paliesthesia, bareesthesia and batiesthesia), hyperreflexia, and bilateral Babinski sign.

*Complementary Tests*

Laboratory: Negative for HIV, Non-reactive VDRL, CBC parameters at the lower normal limit, with no significant morphological alterations in the peripheral smear. ANA and ANCA, ruled out connective tissue disorders. Serum cobalamin, methylmalonic acid and homocysteine: not available.

Abdominal Ultrasound and Chest X-ray: Unremarkable findings.

Imaging: Cervical and lumbar spinal MRI showed no abnormalities; cranial MRI was unremarkable.

Nerve Conduction Studies: Abnormal, with no evidence of peripheral neuropathy or primary peripheral nervous system (PNS) involvement. Somatosensory evoked potentials (SSEPs) revealed absent cortical responses with relative preservation of peripheral sensory responses, suggesting proprioceptive pathway impairment at the posterior columns (figure 1).

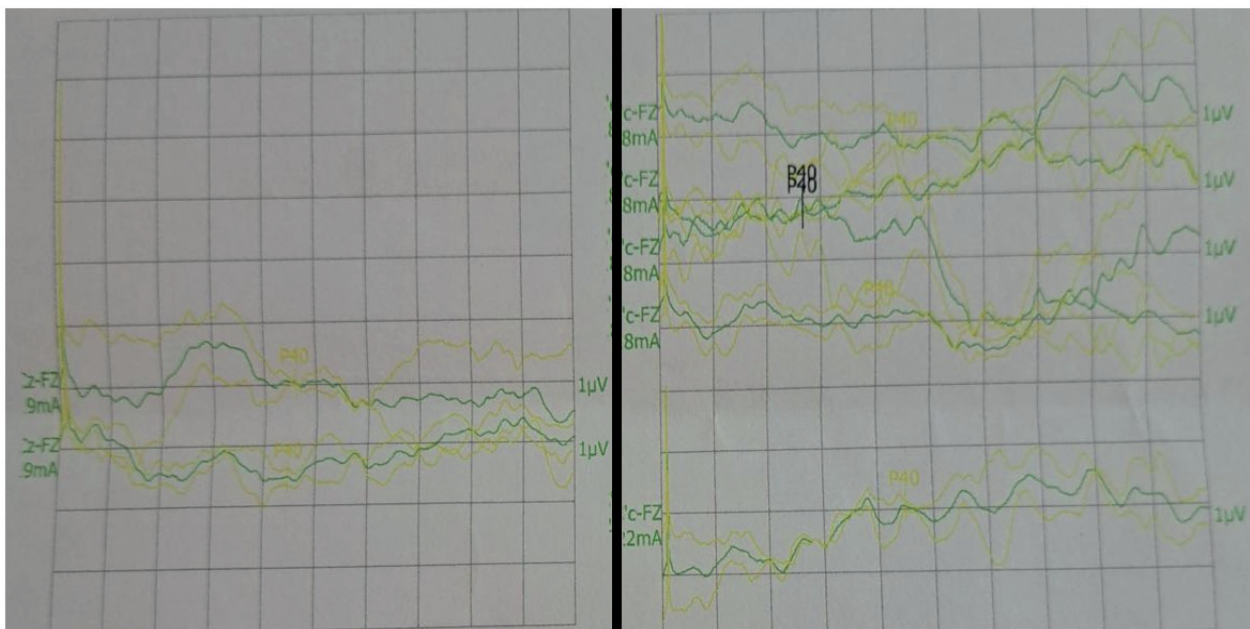


Figure 1. Somatosensory evoked potentials (right and left side).

Given the clinical presentation, including the mild improvement with vitamin B12 use, the physical examination and the test findings, a diagnosis of Subacute Combined Degeneration due to Vitamin B12 deficiency was established, despite not having checked serum cobalamin, methylmalonic acid and homocysteine levels. Vitamin B12 replacement therapy and rehabilitative therapy were initiated and his some of his symptoms improved considerably in the following weeks.

## DISCUSSION

The most common cause of SCD is vitamin B12 deficiency, but there are less common yet important causes to recognize in clinical practice, such as the use and misuse of certain medications (metformin, proton pump inhibitors, and nitrous oxide) or copper deficiency.<sup>(5)</sup> There was no history that led to the less common causes in this patient.

Hirakata *et al.*<sup>(4)</sup> reported a case of an 86-year-old man with numbness in both hands, high-signal-intensity lesions on T2-weighted spinal cord MRI, and myelodysplastic syndrome with elevated serum vitamin B12. However, in patients with vitamin B12 deficiency, more frequently, the serum cobalamin can be low, in the borderline or normal range; plasma methylmalonic acid and homocysteine are particularly useful in this situation to help confirm cellular vitamin B12 deficiency.<sup>(3)</sup> Unfortunately, in this patient, it was not possible to run these tests.

Corredor *et al.*<sup>(6)</sup> reported a similar case in a 79-year-old male with a three-month disease course and additional neuropsychiatric symptoms.

Ryan *et al.*<sup>(7)</sup> reported a case of a 29-year-old female with significant recent life stressors and otherwise unremarkable medical history who presented with progressive weakness of the bilateral lower extremities, admitted to the emergency department with an initial MRI normal. On the other hand, the literature supports improving imaging after supplementation, mainly if patients receive early diagnosis and treatment.<sup>(3,5,8)</sup> In our patient, there were unremarkable findings in the spinal cord MRI. This raises an important question: Could the initial prescription of vitamin B12 have significantly influenced these results?

SCD has a subacute or chronic onset with hidden initial symptoms. Atypical cases are often misdiagnosed. Electrophysiological tests aid in early diagnosis, lesion localization, and severity assessment.<sup>(9)</sup> In this patient, neurophysiological studies revealed absent cortical responses in SSEPs with relative preservation of peripheral sensory responses, confirming proprioceptive pathway impairment at the posterior columns.

## CONCLUSIONS

Subacute Combined Degeneration is a neurological disorder caused mainly by vitamin B12 deficiency, leading to spinal cord damage. Prompt identification and intervention are vital for the recovery from the deficiency.

## REFERENCES

1. Pourshams IA, Arora M, Nimkar S, Kumbham P. Whip It Good: A Case of Vitamin B12 Deficiency and Subacute Combined Degeneration of the Spinal Cord. *Cureus*. 2024; 16(11):e74620. <https://doi.org/10.7759/cureus.74620>
2. Hayashi T, Mori N. Subacute Combined Degeneration of the Spinal Cord. *Intern Med*. 2023; 62(6):951-952. <https://doi.org/10.2169/internalmedicine.0054-22>
3. Díaz J, Puentes G, Saguier I, Folgar SS, Mercado FCB. Degeneración combinada subaguda por déficit de B12. *Medicina (B Aires)*. 2024; 84(2):398. <https://pubmed.ncbi.nlm.nih.gov/33683540>
4. Hirakata K, Ishii Y, Yoshida T, Tanaka F, Nakae Y. A case of diagnosed pernicious anemia and subacute combined degeneration of the spinal cord with abnormally elevated serum vitamin B12. *Rinsho Shinkeigaku*. 2025; 65(2):120-124. <https://doi.org/10.5692/clinicalneuro.002023>
5. Saji AM, Lui F, De Jesus O. Spinal Cord Subacute Combined Degeneration. *StatPearls*. 2024. <https://www.ncbi.nlm.nih.gov/books/NBK560728/>
6. Corredor AB, Olarte CA. Degeneración combinada subaguda. *Acta Neurol Colomb*. 2023; 39(2):e10. <https://doi.org/10.22379/anc.v39i2.872>
7. Ryan CJ, Tolby N. Subacute Combined Degeneration of the Spine: A case Study of Delayed Diagnosis in the Emergency Department. *Cureus*. 2024; 16(8): e67764. <https://pubmed.ncbi.nlm.nih.gov/39323668>
8. Wang R, Chen XY, Yu SY, Yang F, Chen HM, Huang XS. Electrophysiological features of patients with subacute combined degeneration. *Zhonghua Yi Xue Za Zhi*. 2020; 100(13):1023-1027. <https://pubmed.ncbi.nlm.nih.gov/32294861>
9. Demko AW, Rustom DH. Progressive Decrease in Function and Ambulation Potential: A Case of Subacute Combined Degeneration. *Cureus*. 2024; 16(7):e64027. <https://pubmed.ncbi.nlm.nih.gov/39109098>

**INFORMED CONSENT**

The authors confirm that permission was obtained to use the diagnostic images included in this article.

**FINANCING**

No financial support was received for this study.

**CONFLICTS OF INTEREST**

The authors declare no conflicts of interest.

**AUTHORSHIP CONTRIBUTION**

*Conceptualization:* Lisbel Garzón Cutiño, Maytee Olivera Vega.

*Data Curation:* Lisbel Garzón Cutiño, Amanda López Reyes, Luis Daniel Guzmán Camps.

*Formal Analysis:* Lisbel Garzón Cutiño, Maytee Olivera Vega.

*Investigation:* Lisbel Garzón Cutiño, Lianet Pérez Esquivel.

*Methodology:* Lisbel Garzón Cutiño, Lianet Pérez Esquivel.

*Project management:* Lisbel Garzón Cutiño, Lianet Pérez Esquivel.

*Resources:* Lisbel Garzón Cutiño, Deborah Cabrera Rodríguez.

*Software:* Lisbel Garzón Cutiño, Amanda López Reyes, Luis Daniel Guzmán Camps.

*Supervision:* Lisbel Garzón Cutiño, Maytee Olivera Vega.

*Validation:* Lisbel Garzón Cutiño, Lianet Pérez Esquivel.

*Dispay:* Lisbel Garzón Cutiño, Lianet Pérez Esquivel, Deborah Cabrera Rodríguez.

*Writing - Original Draft:* Lisbel Garzón Cutiño, Amanda López Reyes, Deborah Cabrera Rodríguez.

*Writing - proofreading and editing:* Lianet Pérez Esquivel, Deborah Cabrera Rodríguez.